

# Indirect bonding technique in lingual orthodontics: the HIRO system

Toshiaki Hiro\*, Fernando de la Iglesia\*\*, Puigdollers Andreu\*\*\*

\*DDS, PhD, EBO.

\*\*DDS, PhD, Professor Orthodontics of the University International Of Catalunya.

\*\*\*DDS, PhD, Chairman of Orthodontics of the University International Of Catalunya.

Correspondence to:  
Fernando de la Iglesia  
C/ Emancipación 20 1º1º  
Barcelona 08022  
SPAIN

## Introduction

In the early 70's, lingual orthodontics made a sensational debut, and the number of initiated cases increased exponentially. A few years later, the number of lingual orthodontic cases decreased greatly<sup>1</sup>. The reason was very clear; most doctors could not achieve satisfactory results with lingual orthodontics. Since then, there are a few who practice lingual orthodontics and there are limited numbers of finished treatments. As time passed and problem solving associated with lingual orthodontics were improved, lingual orthodontics expanded around the World, specifically in European and Asiatic

The indirect bonding technique is pivotal for success in lingual orthodontics. There are different laboratory techniques available for indirect positioning and bonding of lingual brackets. The HIRO system is one of the most used and easy to perform. In this article the HIRO laboratory and bonding technique and the different innovations and improvements made to the previously described technique are presented.

Hiro T, De la Iglesia F, Puigdollers A. Indirect bonding technique in lingual orthodontics: the HIRO system. Prog Orthod 2008;9(2):34-55.

countries. Today, lingual orthodontics is no longer a technique for limited numbers of orthodontists<sup>2</sup>.

One of the most dramatic changes can be found in the evolution of the bonding procedures. Current bonding procedure is totally different from that of ten years ago. In the 90's orthodontists favoured the use of the silicone tray indirect bonding system. However, this technique didn't satisfy many orthodontists because of its lack of accuracy in indirect bonding.

**Other techniques began to develop and were based in an ideal arch to perform indirect bonding<sup>3</sup>.** Dr. Hiro developed at the beginning of 1990 a laboratory system and indirect bonding technique that was published in 1998<sup>4</sup>. The author described this technique as the Resin Core Indirect Bonding System (RCIBS). This techni-

que had a great impact in the lingual orthodontic world and was called the HIRO System.

Every single laboratory and indirect bonding technique must match the following objectives: easy to make, provide accurate bonding, free from bonding failure, rebondable

and low cost. In this article we will explain the HIRO laboratory and bonding technique and explain the different innovations and improvements made to the previously described technique<sup>4</sup>.

The laboratory and indirect bonding HIRO technique.

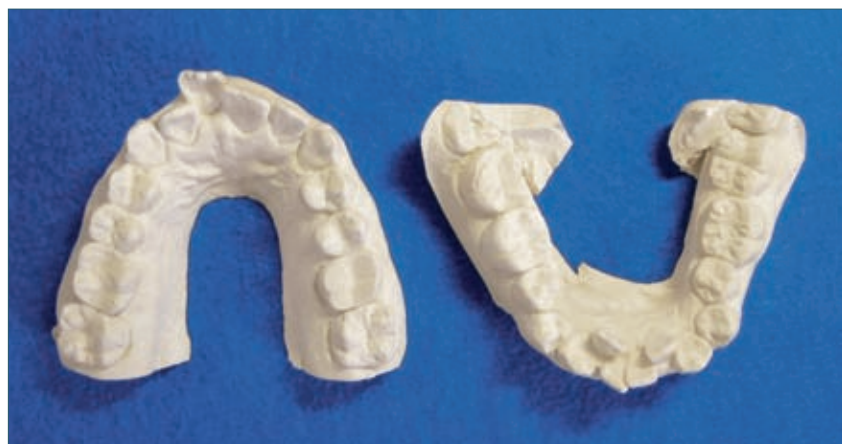

Fig. 1 Hard plaster models.

*La tecnica di bonding indiretto è un elemento fondamentale per la riuscita di un trattamento ortodontico linguale. Esistono attualmente diverse tecniche di laboratorio per il posizionamento e il bonding indiretto dei bracket linguali. Il sistema HIRO rappresenta una delle soluzioni di utilizzo più frequente ed agevole. Il presente articolo illustra la tecnica HIRO e i numerosi miglioramenti ed innovazioni apportati alla versione precedentemente descritta.*

**Key words:** Lingual orthodontics, Lingual Indirect Bonding technique, HIRO system.

*1. Impressions of the patient's mouth (Fig. 1)*

The impressions of the patient's mouth can be taken with silicone, polyether or alginate if you can use a vacuum mixer. The models should be poured with hard plaster.

*2. Setup (Fig. 2)*

Next fabricate the setup with a three point articulator.

*3. Prepare the ideal archwire (Figs 3-4)*

Once the setup has been finished with wax, begin to bend an ideal archwire using the same width as the slot of the brackets that are going to be used (example: with a slot .018 bracket, we will use a .018 x .025 ss archwire). The bended archwire must follow the lingual arch form and must be as symmetrical as possible.

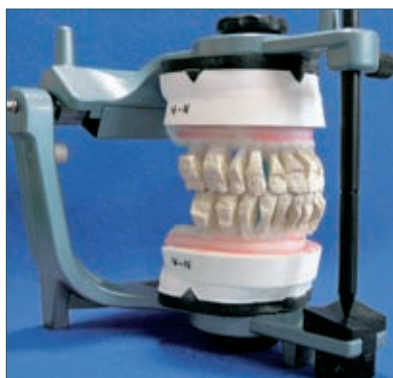

Fig. 2a,b Models setup.

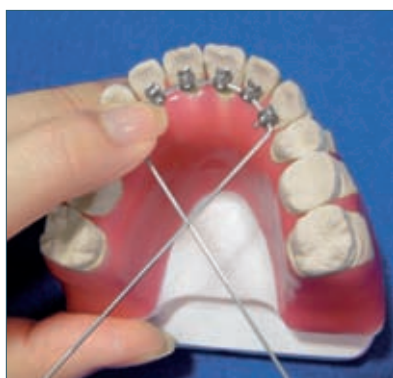
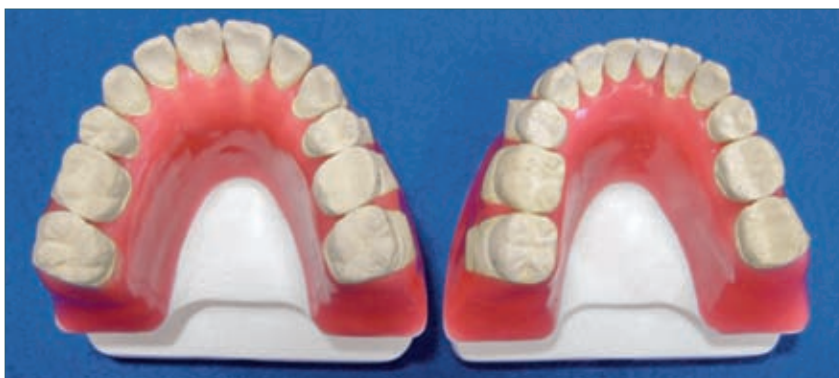
Fig. 3 Bending the wire.

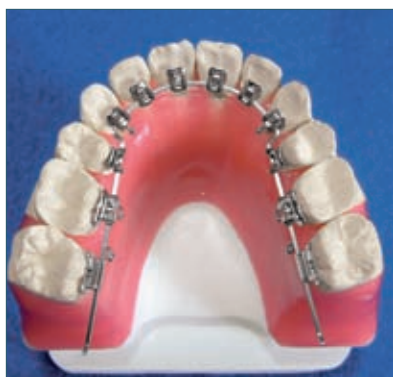

Fig. 4 Ideal archwire.

Before doing the premolar bend, it is advisable to position the six anterior brackets initially. This will make the brackets have the smallest possible gap between the mesh pad and the tooth's lingual surface. Sometimes, the bracket form does not adapt to the dental anatomy, so we will have to make adjustments to the mesh pad

by grinding or bending it. The brackets must be positioned in the gingival or inferior third of the tooth. This positioning will help the patient's speech and occlusion by not creating any interferences. If we observe that the premolars have a very short clinical crown, a vertical step-down can be made on the archwire to compensate; another option is to build up the lingual cusp with composite resin.

If a step-down is made in the ideal archwire, this bend must be reproduced in the final archwires at the end of the treatment.

#### 4. Position the surgical hooks (Figs 5-6)

Once the ideal arch has been done and the brackets are correctly positioned in the centre of the teeth, remove the arch wire from the setup and crimp three surgical hooks on

La technique indirecte de bonding est prioritaire pour le succès dans l'orthodontie linguale. Il y a différentes techniques de laboratoire disponibles pour le positionnement et le collage indirects des brackets linguales. Le système de HIRO est une de plus employée et facile à exécuter. En cet article la technique de laboratoire et de collage de HIRO et les différentes innovations et améliorations apportées à la technique précédemment décrite sont présentées.

Traduit par Maria Giacinta Paolone

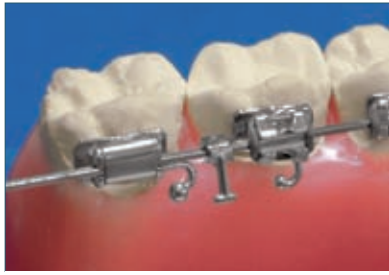

Fig. 5a,b Crimped surgical hooks.

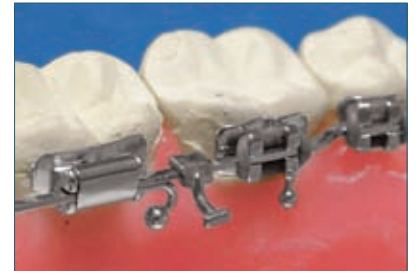
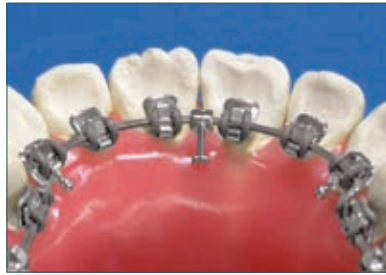
Fig. 6 Bend the surgical hooks lingually.

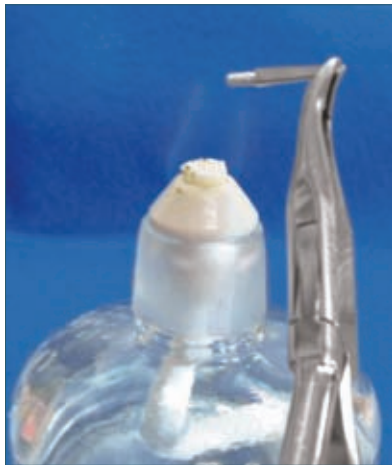

Fig. 7 Heat the dosel pins.

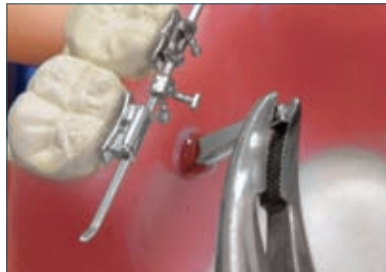
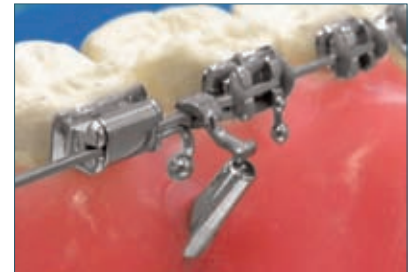
Fig. 8a,b Stick the dosel pins under the surgical hooks.



the wire. This will help position the archwire in the setup. The hooks will be positioned between the two central incisors and between the

first and second molars in both sides. Afterwards the surgical hooks are bent lingually.

5. *Position the dowel pins (Figs 7-9)*  
Next, heat three dowel pins and stick them in the wax base just under the surgical crimped hooks.

6. *Fabricate the acrylic resin hoods (Figs 10-11)*

Once the dowel pins are fixed in the wax the next step is to fabricate the acrylic resin hoods powder-liquid that will help position the archwire exactly when rebonding. Use gutta-percha at two points of the arch to keep the wire for a

*La cementación indirecta es una técnica fundamental para el éxito en el tratamiento ortodóncico lingual. Existen diferentes técnicas de laboratorio disponibles para el posicionamiento indirecto y la cementación con brackets de la técnica lingual. El sistema HIRO es uno de los más utilizados y fáciles de aplicar. En este artículo, se presentan las diferentes innovaciones de cementación propuestas por el laboratorio HIRO con respecto a las técnicas descrita anteriormente.*

Traducido por Santiago Isaza Penco

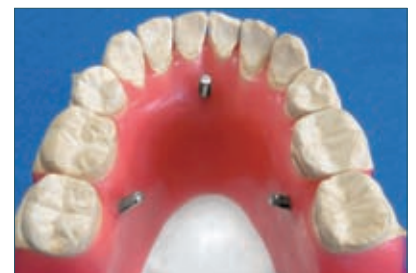

Fig. 9 Dosel pins positioned.

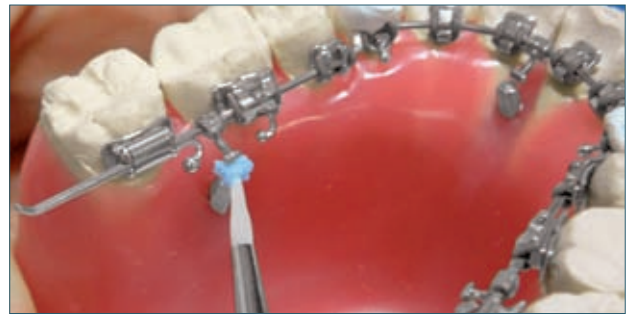
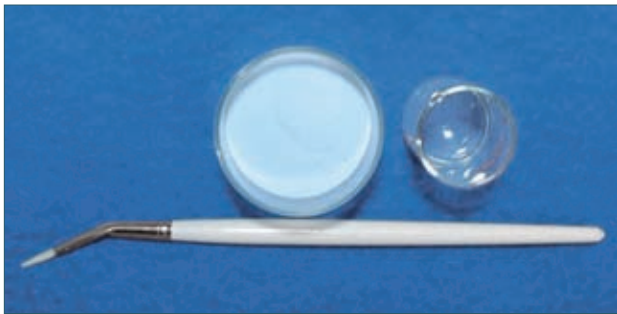

Fig. 10a,b Fabricate the acrylic resin hoods.

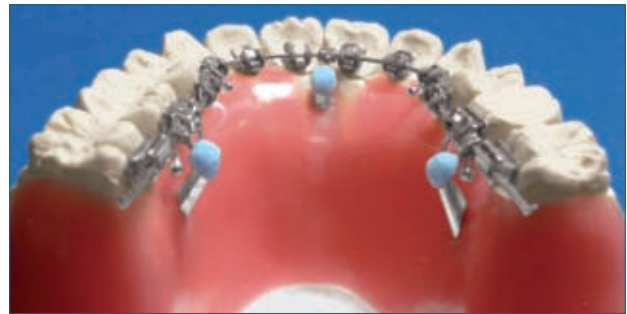
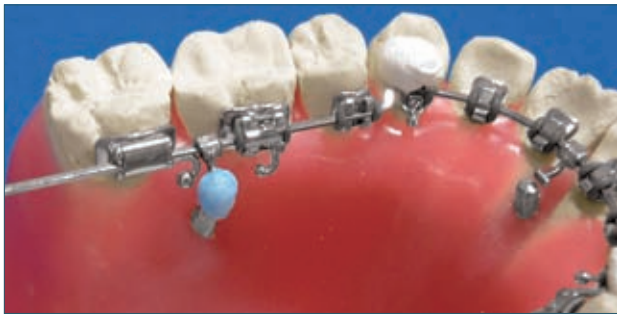

Fig. 11a,b Acrylic resin hoods fabricated.

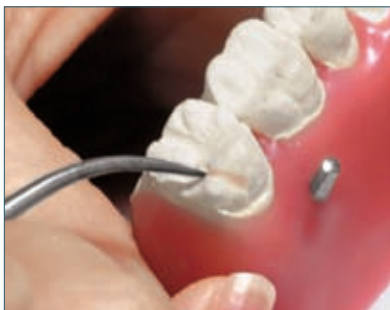

Fig. 12 Block out the molar small grooves with wax.

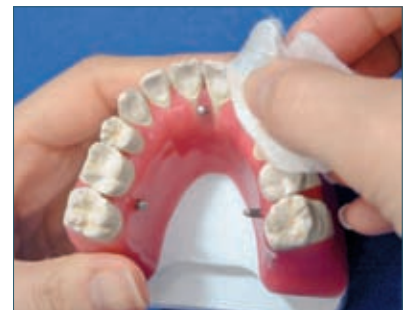

Fig. 13a,b Soap the casts and polish them afterwards.

short time in its position until the acrylic resin hoods have been finished (observe the detail of the gutta-percha on top of the arch at the canine). When making the acrylic resin hoods the resin must cover the crimped surgical hooks totally and the dowel pins partially. Now the ideal archwire can be positioned exactly in the model at any time thanks to the acrylic resin hoods and the dowel pins.

7. Prepare the models (Figs 12-13) Subsequently, block out the molar

small grooves with wax to prevent them from being retentive when the rigid cores are being constructed. Next soap the casts for 3 to 4 hours and polish them afterwards. Soaping the models is done instead of applying separator. Since the separating layer of soaping is quite thin the brackets can be bonded much more precisely comparing it with applying separator to the model.

8. Transfer the information from the setup to the bracket (Fig. 14) The next step is to transfer all the in-

formation of the setup to the brackets. First we will apply light cure composite resin (Transbond®3M) on the bracket bases. Position the archwire in the setup with the help of the acrylic resin hoods. Then cure all the light cure composite resin of the bracket bases. Now all the information of the setup has been transferred to the brackets.

9. Construction of the resin cores (Figs 15, 16 and 17)

This is the time to begin the construction of the transfer resin cores.



Fig. 14a,b Apply light cure composite resin on the brackets bases and position the ideal archwire.

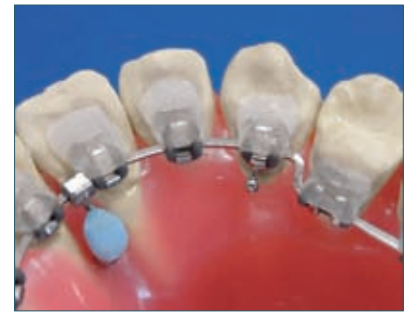
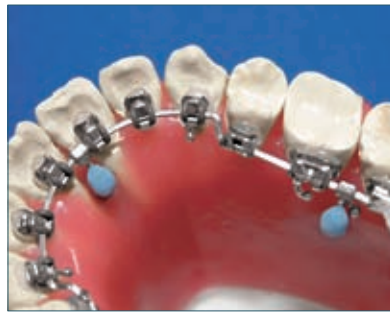
Fig. 15 Cover all the brackets with provisional dental resin ( Fermit®).

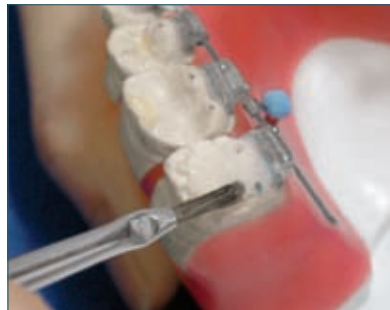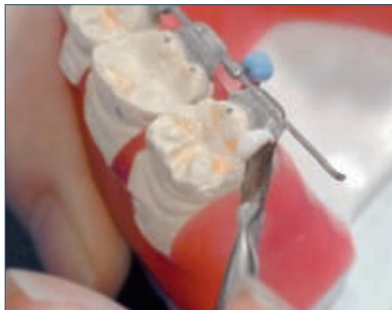


Fig. 16a,b Use a liquid-powder acrylic resin to construct the resin cores.

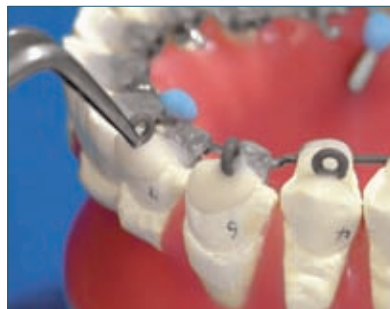

Fig. 17a,b Elastic ring positioning.

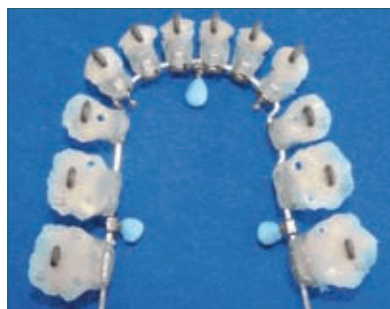
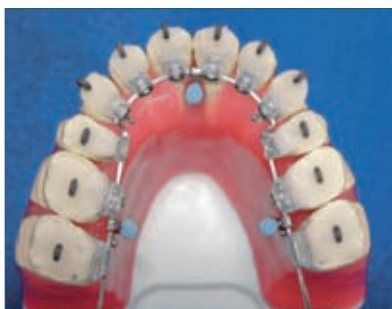
Fig. 18a,b Transfer resin cores finished.

First cover all the brackets with provisional dental resin (Fermit® Vivadent) paying special attention in not covering the ideal archwire and co-

vering 1-2 mm of the teeth beyond the bracket's base. This material adheres to the brackets and its elasticity makes the removal of the resin cores

easy. Do the same for all the brackets and cure the provisional dental resin (Fermit® Vivadent).

The next step is to mark with a pencil the lingual functional cusps of molars and premolars. This will help as a reference guide for re-checking the height of the brackets. The brackets must never be positioned higher than the functional cusps. Another reason for marking the cusps with a pencil is to leave a small hole in the resin core. This will permit the excess of adhesive to come out. Afterwards use a powder-liquid acrylic resin to construct the resin cores and before the acrylic has hardened put an elastomeric ring that will help afterwards transfer the individual resin cores from the model casts to the patient's mouth.

#### 10. Polish the resin cores

(Figs 18-20)

Once all the resin cores have been completed, they are numbered according to the tooth and separated from the setup. Excess resin is ground off and a heated instrument used to cut the elastomeric ligatures. This allows for separation of the resin core from the ideal archwire. At this time, all the transfer resin cores are done and the bonding can begin.

11. - Picture of the transfer resin cores (Fig. 21)

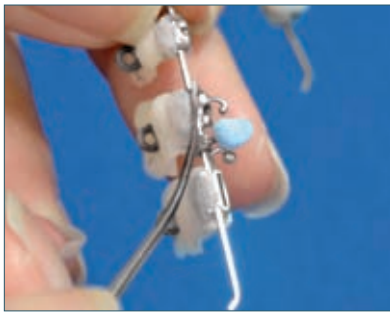


Fig. 19a,b Grind off the excess resins and cut the elastic ligatures.

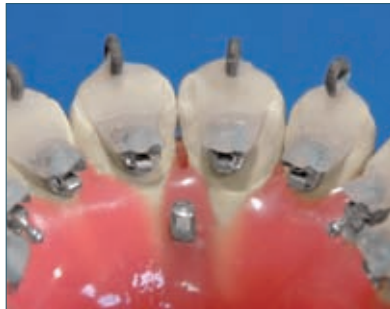
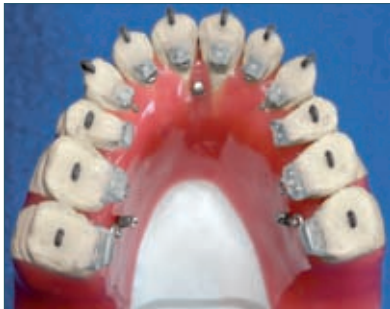
Fig. 20a,b Transfer resin cores ready to be bonded.

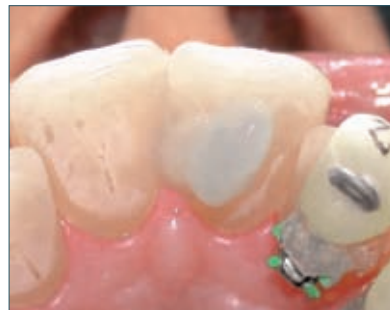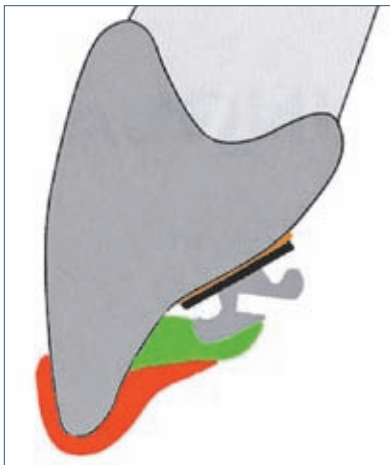


Fig. 22 Etch the lingual surface with orthophosphoric acid.

Fig. 21 Transfer resin cores.

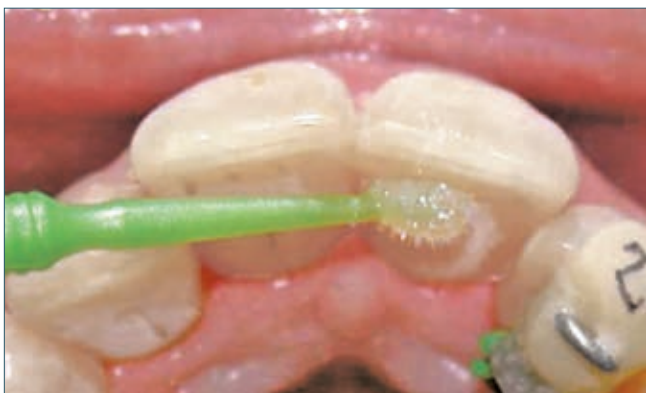

Fig. 23 Apply a thin coat of bond to the etched surface.

## Bracket bonding

The bonding technique is simple but has some peculiarities. First, the teeth must be etched with orthophosphoric acid. (Fig. 22). After 15 seconds rinse with water and dry. Apply a thin coat of bond to the etched surface (Fig. 23) and afterwards apply a very small amount of bond and light-curing composite to the bonding surface of the bracket. (Transbond®) (Fig. 24). Carefully pick the transfer resin core by the elastomeric ring (Fig. 25) and seat the resin core on the corresponding tooth. Using a light-curing lamp, cure for at least 20 seconds (Fig. 26). Subsequently with a pointed instrument separate the acrylic resin from the transfer core (Fig. 27). Then take off the provisional dental resin (Fermi®) from the bracket. Now the bracket is rea.

## Bracket rebonding

Any indirect bonding technique in lingual orthodontics must be easy and quick to perform when rebonding brackets. With the HIRO system, rebonding of brackets is easy and can be done in the office in a short period time. The transfer resin cores used at the beginning of treatment cannot be used again for rebonding. Firstly, the new bracket is positioned on the ideal wire of the setup with an elastomeric ring. Afterwards seat the ideal wire in the setup using the acrylic resin hoods (Fig. 28). Next, build up the transfer resin core as shown in figures 14-17. First apply light-curing composite (Transbond®) in the bonding surface of the bracket, cover partly the bracket with provisional dental resin (Fermi®) and subse-

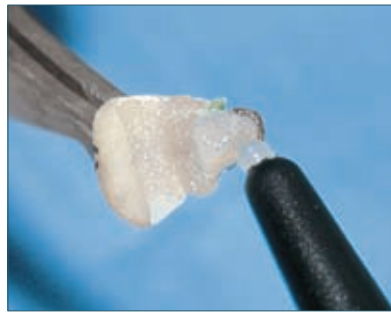
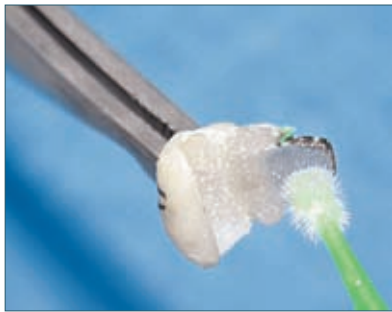

Fig. 24a,b Apply a very small amount of bond and lightcuring composite.

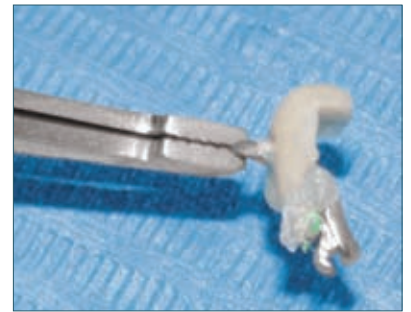

Fig. 25 Pick the transfer resin core.

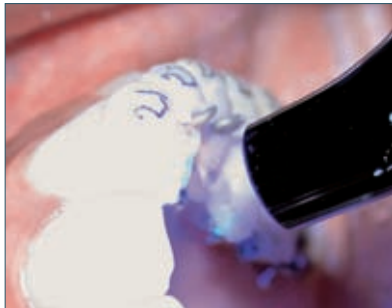

Fig. 26 Seat the resin core and cure.

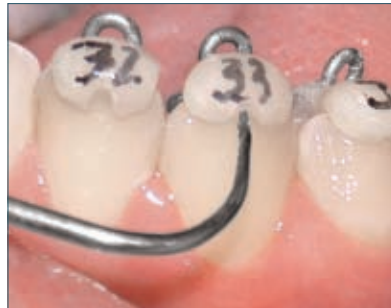

Fig. 27 Separate the acrylic resin from the transfer core.

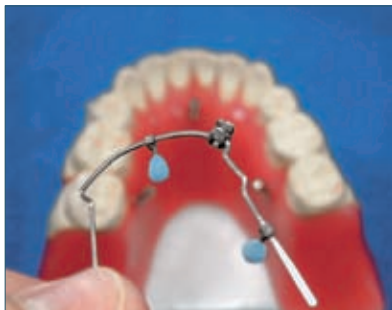

Fig. 28a,b Rebonding of brackets. Seat the ideal wire using the acrylic resin hoods.

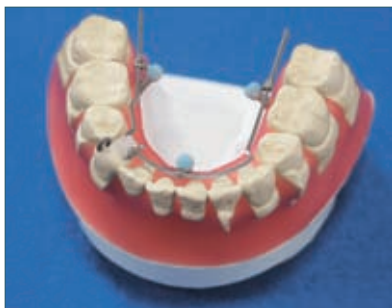
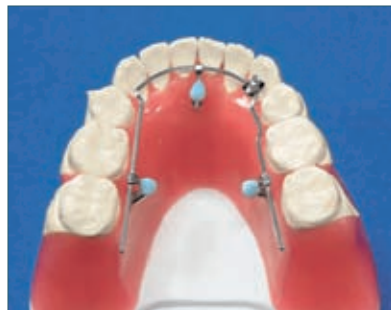
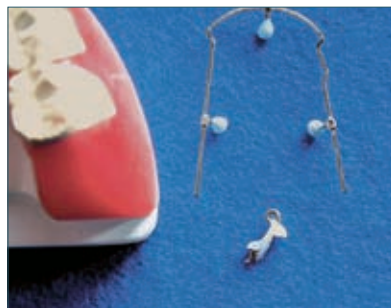Fig. 29a,b Transfer resin core finished.



quently add liquid-powder acrylic resin to build up the resin cores. It takes just 3 minutes to build up the transfer resin core (Fig. 29).

### Clinical case

A 26-year-old woman was referred for orthodontic consultation. Her chief complaint was her crowded teeth.

She had no history of physical trauma to the head or neck. The patient had a convex profile with a symmetric face and lip competence at rest. Intraorally, she had a bilateral Class I molar and canine relationship. She had a correct overjet and 2 mm of overbite. The maxillary arch was U-shaped with mild crowding. The mandibular arch also was U-shaped and had mild crowding. The cephalometric analysis showed a skeletal Class II anteroposterior discrepancy with an ANB angle of  $6,2^\circ$  and a normofacial pattern, as shown by an SN-GoGn of  $38^\circ$ . The lower incisors were excessively protruded as shown by an IMPA of  $101,7^\circ$ . (Fig. 30).

The treatment plan was not to protrude the upper and lower incisors and solve the upper and lower crowding. The decision taken was to extract the first upper and lower premolars. Figures 31- 34 shows the patient's evolution. Orthodontic treatment lasted 20 months. An acceptable occlusion was obtained. Figure 35 shows the three year follow-up. The superimposed cephalometric tracings (Fig. 36) show a correct incisor inclination at the end of treatment.

### Discussion

There are many different indirect